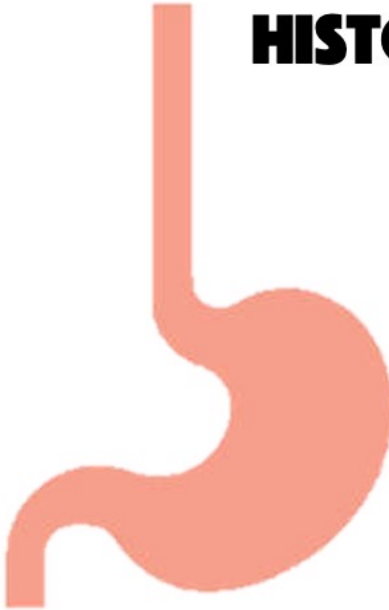


# FOREIGN BODY INGESTION



**#1 cause**

## HISTORY



Esophageal

- Choking/Gagging
- Vomiting
- Dysphagia/Odynophagia
- Coughing
- Refusal to eat

Stomach

- MOST Asymptomatic**
- Gastric Outlet Obstruction RARE

**50% HAVE NO SIGNS  
OR SYMPTOMS**

# FOREIGN BODY INGESTION

## EMERGENT ENDOSCOPY



Button Battery in Esophagus

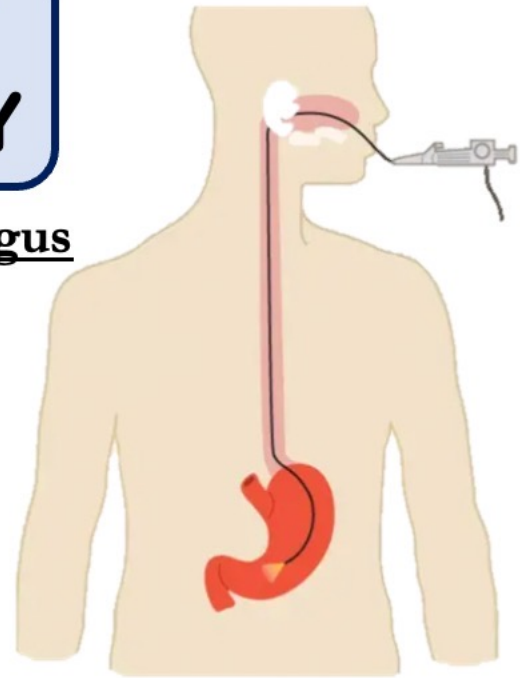
Airway Compromise

Sharp/Pointed Object\*

Multiple Magnets\*

Esophageal FB impacted > 24h

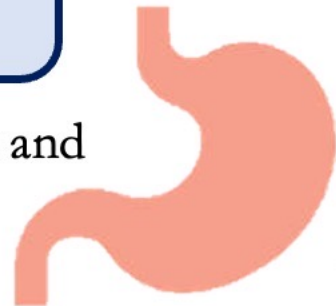
Obstruction



*\*any location\**

## EXPECTANT MGMT

Asymptomatic → Stomach and  
beyond



# FOREIGN BODY INGESTION



WORKUP

**SICK**

Resuscitate

**STABLE**

AP & Lateral XRAY

Neck  
Chest  
Abdomen

LOCATION & SIZE

**TRACHEAL**

**ESOPHAGEAL**



THINK COIN SLOT  
IN TRACHEA

**AP**  
SAGGITAL  
PLANE

**AP**  
CORONAL  
PLANE

**LATERAL**  
EN FACE

**LATERAL**  
TANGENTIALLY,  
POSTERIOR TO  
TRACHEAL AIR

